




Efficiency of Imaging Modalities in Male Breast Disease: Can Ultrasound Give Additional Information for Assessment of Gynecomastia Evolution?

Özgür Sarıca¹ , A. Nedim Kahraman² , Enis Öztürk³ , Memik Teke¹ 

¹Department of Radiology, Taksim Gaziosmanpaşa Training and Research Hospital, İstanbul, Turkey

²Department of Radiology, Fatih Sultan Mehmet Training and Research Hospital, İstanbul, Turkey

³Department of Radiology, Bakırköy Training and Research Hospital, İstanbul, Turkey

ABSTRACT

Objective: The purpose of this study is to present mammography and ultrasound findings of male breast lesions and to investigate the ability of diagnostic modalities in estimating the evolution of gynecomastia.

Materials and Methods: Sixty-nine male patients who admitted to Taksim and Bakırköy Education and Research Hospitals and underwent mammography (MG) and ultrasonography (US) imaging were retrospectively evaluated. Duration of symptoms and mammographic types of gynecomastia according to Appelbaum's classifications were evaluated, besides the sonographic findings in mammographic types of gynecomastia.

Results: The distribution of 69 cases were as follows: gynecomastia 47 (68.11%), pseudogynecomastia 6 (8.69%) primary breast carcinoma 7 (10.14%), metastatic carcinoma 1 (1.4%), epidermal inclusion cyst 2 (2.8%), abscess 2 (2.8%), lipoma 2 (2.8%), pyogenic granuloma 1 (1.4%), and granulomatous lobular mastitis 1 (1.4%). Gynecomastia patients who had symptoms less than 1 year had nodular gynecomastia (34.6%) as opposed to dendritic gynecomastia (61.5%) ($p < 0.01$) based on mammography results according to Appelbaum's classifications. In patients having symptoms for 1 to 2 years, diffuse gynecomastia (70%) had a higher rate than the dendritic type (20%). Patients having the symptoms more than 2 years had diffuse gynecomastia (57.1%) while 42.9% had dendritic gynecomastia ($p < 0.001$). With sonographic examination patients who had symptoms less than 1 year had higher rates of dendritic gynecomastia (92.3%) than nodular type (1.9%). Patients having symptoms for 1 to 2 years had more dendritic gynecomastia (70%) than diffuse type (30%). Patients having symptoms more than 2 years had diffuse gynecomastia (57.1%) comparable to dendritic gynecomastia (42.9%).

Conclusion: Diagnostic imaging modalities are efficient tools for estimation of gynecomastia evolution as well as the diagnosis of other male breast diseases. There seems to be an incongruity between duration of clinical complaints and diagnostic imaging classification of gynecomastia. The use of these high resolution US findings may demonstrate an early phase fibrosis especially in patients visualized by mammography as with nodular phase.

Keywords: Male breast, gynecomastia, breast cancer, ultrasound, mammography, imaging

Cite this article as: Sarıca Ö, Kahraman AN, Öztürk E, Teke M. Efficiency of Imaging Modalities in Male Breast Disease: Can Ultrasound Give Additional Information for Assessment of Gynecomastia Evolution? Eur J Breast Health 2018; 14: 29-34.

Introduction

Most male patients who have breast complaints admit with similar symptoms and physical examination findings. Overwhelming majority of male breast problem is benign and includes gynecomastia (1). Male breast cancer forms 0.17% of all male cancers and 0.5-1% of all breast cancers (2). The key point to distinguish gynecomastia from a malignant mass is the presence of a palpable lump without a mass located beneath the nipple or skin thickening neither nipple retraction. Despite these indicators, it is not easy to distinguish gynecomastia from malignant masses with physical examination. Previously, imaging was not performed in men with a palpable breast mass (3). A high positive predictive value, sensitivity and specificity have been reported for both mammography (MG) and breast ultrasound (US) for diagnosing male breast cancer (4-6). Therefore, it is critically important to differentiate benign and malignant masses with imaging modalities.

Radiological findings of gynecomastia vary according to the developmental stage. Appelbaum (7) has classified MG patterns of gynecomastia in regard with the pathological development phases. However, the success to demonstrate gynecomastia and its developmental phases by US is less discussed in the literature.

Address for Correspondence:

Özgür Sarıca, e-mail: sozgur@yahoo.com

Received: 08.01.2017
Accepted: 11.07.2017

There are no standardized algorithms for the evaluation of the male breast disease. Currently, the recommended protocol for palpable mass in male patients is to perform x-ray MG (to distinguish gynecomastia from pseudogynecomastia and to identify suspicious lesions) followed by high-frequency breast US (8). Some studies suggest that US is widely accessible and furthermore, MG is not preferable in young adults. Therefore US imaging can be used as first-line imaging modality (4).

Considering the current conflict in the literature, the purpose of this study is to present mammography and ultrasound findings of male breast lesions and to search the ability of diagnostic imaging modalities in estimating the evolution of gynecomastia.

Materials and Methods

Patients: Sixty-nine male patients who underwent MG and US in two different radiology departments between January 2008 and December 2010 were retrospectively evaluated.

The clinical presentations of these patients were categorized into four groups: Unilateral or bilateral breast enlargement, palpable mass, tenderness or pain, more than one of these symptoms.

The cases which were not evaluated by both MG and US were excluded. Lumpectomy, mastectomy, or core biopsy samples (if present) were evaluated at our pathology department. According to our monitoring protocol, radiologic follow-up is performed for at least 2 years in patients without histopathological evaluation. All the US and mammographic images accessed via picture archiving and communication system (PACS) were retrospectively analyzed by two radiologists who have an experience of evaluating more than 1500 diagnostic mammograms per year. Both radiologists were blind about the histopathological reports. The MG and US findings were recorded for each lesion. In cases of discrepancy between the two observers, consensus is achieved by discussion between them.

Mammography scans were performed by Lorad M3 with standard film screen techniques integrated with Computerized Radiography (CR) at the Taksim Hospital whereas mammography scans were performed by using (Siemens MAMMOMAT Novation Digital Radiography DR) at the other hospital. US examinations were done by two different radiology units with same high-resolution US equipment (model LOGIQ 9 with a high-frequency linear transducer with multiple focal zones GE Healthcare.). CR system is an image digitization system designed to acquire and digitize X-ray images from image storage phosphor plates.

Diagnostic assessments; Breast Imaging Reporting and Data System (BI-RADS) category assessments were used to categorize MG and US examination of patients with mass lesions (9).

Pseudogynecomastia-adipomastia refers to breast enlargement in men. The breast enlargement is generally caused by adipose tissue excess, rather than by the growth of the glandular tissue. Clinically it may seem similar to gynecomastia. These two entities can be easily differentiated by mammography which enables determination of fatty tissue. Subareolar densities, which are not apparent in pseudogynecomastia, are also easily recognized in gynecomastia.

The presence and type of gynecomastia were evaluated with mammograms. The mammographic patterns of gynecomastia were grouped according to the criteria defined by Appelbaum et al. (7). We correlated mammographic patterns of gynecomastia with US findings according to Appelbaum classification. US findings are classified as nodular (well

circumscribed-oval shaped), dendritic (spider leg-shaped, angulated) and diffuse (a similar appearance with adult female breast).

Three mammographic patterns of gynecomastia may be represented by degrees and stages of ductal and stromal proliferation (10). These patterns are the nodular, dendritic, and diffuse glandular patterns. Nodular pattern; At MG, there is nodular subareolar density. The density usually blends gradually into the surrounding fat, but it may be more spherical. By using US a well circumscribed ovoid shaped hypoechoic area enclosed by fat tissue also can be detected (Figure 1)

Dendritic pattern (10, 11); Mammograms show star-shaped irregular retroareolar radiodensity which merges with the enclosing fat tissue. The US study presents a heterogeneous hypoechoic area placing the nipple at the center with an irregular posterior border which is surrounded by echogenic fibrous tissue (Figure 2).

At MG Diffuse pattern reveals a widespread radiodensity caused by proliferated fibro glandular tissue as in female breast. US exhibits hyperechoic glandular tissue is found, with increased subcutaneous adipose tissue anteriorly and without the hypoechoic central nodule (12) (Figure 3).

Gynecomastia cases were defined as three groups according to the duration of symptoms. In the first group, symptom duration was less than one year. In the second group symptom duration was between one and two years, whereas in the third group it was more than two years. Duration of symptoms and its relation with gynecomastia subtypes determined in MG were compared statistically.

Statistical analyses; NCSS (Number Cruncher Statistical System) 2007&PASS (Power Analysis and Sample Size) 2008 Statistical Software (Utah, USA) were used for all statistical analysis. In addition to descriptive statistics (frequency, ratio), Chi-square test was used for qualitative data. Values for $p < 0.05$ were accepted as significant.

Informed consent was obtained from patients who participated in this study. No institutional review board approval was required for this retrospective study.

Results

The most common symptom was diffuse bilateral or unilateral breast enlargement without a palpable mass in 45 patients (66%), other symptoms were palpable mass in 21 patients (30%), tenderness or pain in 34 patients (49%), nipple discharge in three patients (7%) and 33 patients have more than one of these symptoms (48%). Two of three patients with hemorrhagic nipple discharge had breast cancer and the other serous one had gynecomastia. One of the 2 patients with a visible lesion at the nipple-areolar complex had papillary breast carcinoma and the other had pyogenic granuloma (Table 1).

In our study, 35 symptomatic patients were younger than 50 years of age. Four of these (11%) had breast carcinoma.

The diagnosis was established in 48 patients (70%) by radiological imaging and in 21 patients (30%; 17 excisional and 4 tru-cut biopsies) by pathological evaluation. Malignant pathological diagnoses among our cases were invasive ductal carcinoma (n=5), papillary carcinoma (n=2) and metastatic carcinoma (n=1). Their ages varied between 38 and 82 years (mean±SD, 57.43±15.78). The mean size (±SD) of the mass was 26.57±12.19 mm (range 6-45 mm) Focal benign lesions were including epidermal inclusion cyst (n=2), abscess (n=2), lipoma (n=2), pyogenic granuloma (n=1), and granulomatous lobular mastitis (n=1). In some cases, gynecomastia and benign or malignant focal lesions were observed together (Figure 4) (Table 2).

Table 1. Radiopathological findings of patients in different age groups

	Gynecomastia	Pseudogynecomastia	Other benign types	Cancer	Total
< 35	19	1	0	0	20 (28.98%)
36-50	4	2	5	4	15 (21.74%)
>51	24	3	3	4	34 (49.28%)
Total	47 (68.11%)	6 (8.69%)	8 (11.60%)	8 (11.60%)	69 (100%)

Our three cases have gynecomastia and also another benign pathology in table 1

Table 2: Mammosonographic findings of malignant primary breast masses

	MG FINDINGS	US FINDINGS
Mass with irregular, ill-defined or lobulated contour	4 /7 (57%)	5/7 (72%)
Mass with well-circumscribed contour	2/7 (28%)	1/7 (14%)
Nipple retraction and skin thickening	1/7 (14%)	1/7 (14%)
Microcalcifications	2/7 (28%)	2/7 (28%)
Number of metastatic lymph node detected *	0/7	3/7 (43%)
<= BI-RADS 3	2/7 (28%)	0/7
BI-RADS 4-5	5 /7 (72%)	6/7 (86%)

*One of three pathologically detected axillary metastatic lymph node has micrometastasis.
MG: mammography; US: ultrasound; BI-RADS: Breast Imaging Reporting and Data System

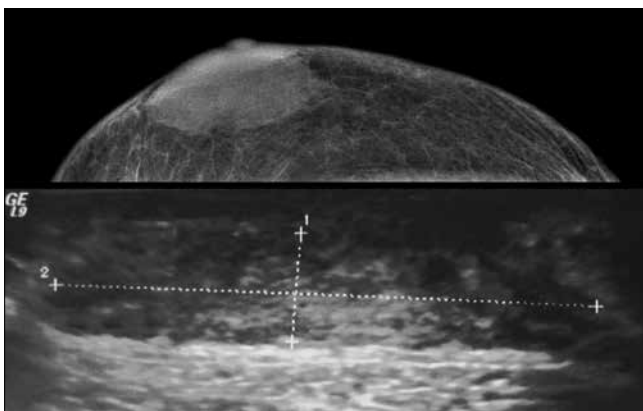


Figure 1. Pathologically proven nodular gynecomastia. Ultrasound demonstrates well-defined discoid area

Five of seven primary malignant masses were visible on mammography (72%) whereas six of them were visible by US (86%). The only case diagnosed as intraductal papillary carcinoma located in the nipple (<5mm) was invisible with US. All the masses were hypoechoic and completely solid (86%) except one which includes cystic areas (14%).

In our study, microcalcified masses were demonstrated on mammograms in two of cases. The first patient had uniform, dense, widely scattered and punctate microcalcification, while the other had partially

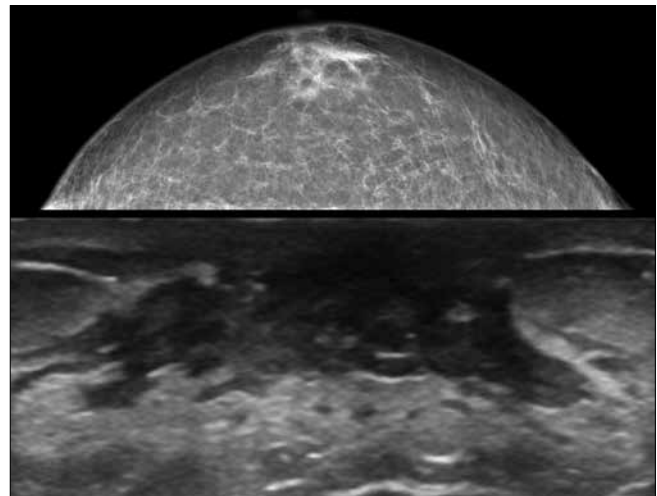


Figure 2. Typical appearances of dendritic gynecomastia (two different patients)

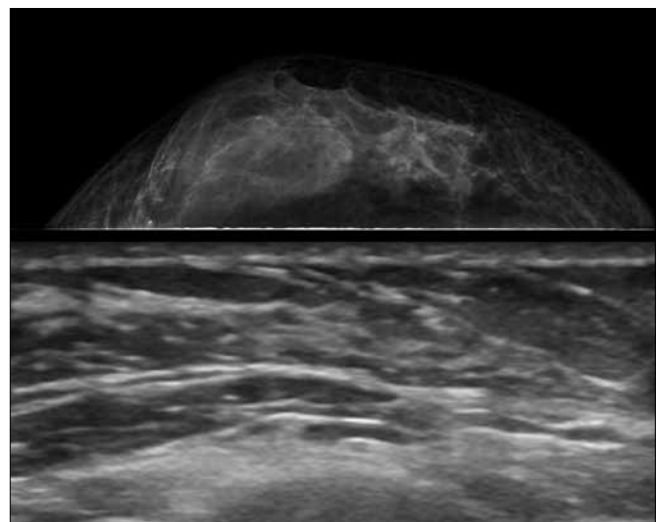


Figure 3. Typical appearances of diffuse gynecomastia

linear, punctate and clustered calcifications. Two of seven carcinoma patients (28%) had coexistent gynecomastia.

Change of posterior acoustic features has been demonstrated only in 2 benign cases (abscess and lobular capillary hemangioma). Two patients had breast abscess; on mammograms, both of them had high-density masses. Ultrasonography revealed well-circumscribed heterogeneous hypoechoic masses in these patients. Pathologically proven epidermal inclusion cysts that are present in two patients, appeared as round, well-circumscribed

Table 3. Duration of symptoms and its relation with mammosonographic gynecomastia subtypes

	<1 year (group 1) n=52(62.7%)		1-2 year (group 2) n=10(12%)		>2 year (group 3) n=21(25.3%)		total n=83(100%)	
	MG	US	MG	US	MG	US	MG (%)	US (%)
	Nodular	18 (%34.6)+	1 (1.9%)	1 (%10.0)	0 (0%)	0 (0%)	0 (0%)	n=19 (22.9%)
Dendritic	32 (%61.5)+	48 (92.3%)	2 (%20)*	7 (70%)	9 (%42.9)*	9 (42.9%)	n=43 (51.8%)	n=64 (77.1%)
Diffuse	2 (%3.8)	3(5.7%)	7 (%70.0)*	3 (30%)	12 (%57.1)*	12 (57.1%)	n=21 (25.3%)	n=18 (21.6%)
Total	52		10		21		83	

MG: mammography; US: ultrasound
+p<0.01, *p<0.001

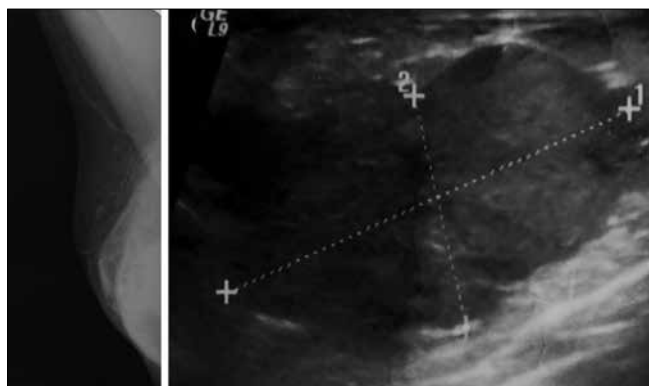


Figure 4. Huge breast mass mimicking diffuse gynecomastia on mammography scan

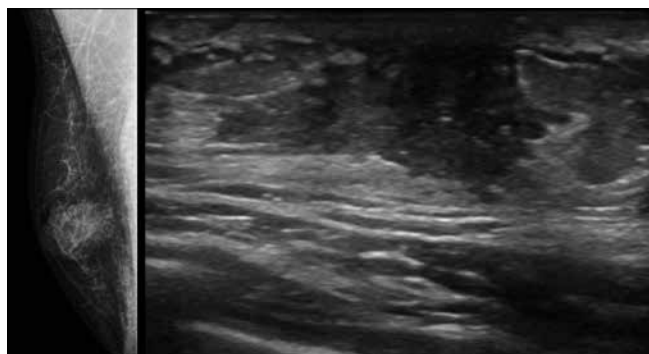


Figure 5. Patient having nodular gynecomastia on mammography had dendritic gynecomastia at ultrasonography

nodules both on mammography and US. Ultrasound demonstrated the gland neck coursing through the skin. A case diagnosed by lobular capillary hemangioma had well circumscribed hypoechoic mass while only focal skin thickening was observed by mammography. Another patient with palpable mass had retroareolar ill-defined hypoecogenic lesion -trucut biopsy reveals granulomatous lobular mastitis.

In 10 of 56 patients were diagnosed with gynecomastia had clinical suspicion of real mass lesion. Only two of those patients had mammosonographically detected a benign mass. Of the remaining eight cases, (14%) which were assumed to be a real mass by clinical breast examination (CBE), were proven to be gynecomastia by both US and mammographic examinations. Six patients (11%) had pseudogynecomastia (adipomastia) as diagnosed by MG. A total of 83 breasts of 50 patients with true gynecomastia were examined. According to MG

findings, gynecomastia was unilateral in 17 cases (34%), and bilateral in 33 cases (66%) (Table 3).

There were 3 patients (5%) who have two phases of gynecomastia simultaneously.

When we statistically compared symptom durations with mammosonographic gynecomastia patterns in group 3 patients, diffuse gynecomastia has been detected significantly more than dendritic gynecomastia (p<0.001). In group 1 patients, dendritic gynecomastia has been detected significantly more than nodular gynecomastia (p<0.01). In group 1 patients mammographic nodular gynecomastia diagnosis was confirmed by sonography in only one patient. He had a well-defined discoid area regarding nodular gynecomastia at sonography. In our study, most of the early phase gynecomastia cases (92%) with the appearance of nodular gynecomastia at MG had dendritic gynecomastia when evaluated by sonography (Figure 5).

Discussion and Conclusion

A proven appropriate algorithm for the evaluation of male breast problems has not been defined. In the past, surgical intervention and percutaneous biopsy in men with a palpable breast mass had been performed without breast imaging (3). However, it has been reported that percutaneous biopsies can lead to misdiagnosis (13). As stated Munn et al. (14) combined use of mammosonography could substantially reduce the need for biopsy. Fourteen percent of our biopsy planned cases, which were interpreted as a mass with clinical examination, were diagnosed as gynecomastia after mammographic examination. Thus, these cases were diagnosed without biopsy.

One percent (1) % of male breast cancers occur under the age of 30 and 6% under 40 years (15) Cooper et al. (16) have reported that men under 50 years with breast enlargement or a palpable, non-indurated central subareolar mass is not required to undergo MG unless there are other clinical indications. In our study, 11% of our symptomatic cases below 50 years of age were cancer. Although imaging was not recommended for such young patients (5, 16) , we believe that diagnostic imaging modalities are necessary for the evaluation of male breast with enlargement or a palpable mass. Hence, avoiding mammographic evaluation will probably increase the need for sonography.

In our study, 62% of the patients had the symptoms less than one year and probably in the reversible state. Gynecomastia is reversible if the causal factors are removed in the early proliferative stages (11, 12). The nodular pattern correlates with the pathologic classification of florid

gynecomastia, which is thought to be the early proliferative phase of gynecomastia (4, 10, 11). At histologic analysis, florid gynecomastia is characterized by hyperplasia of the intraductal epithelium with loose, cellular stroma and surrounding edema. The literature reports that florid phase which corresponds to nodular gynecomastia at MG is more common but we have observed dendritic gynecomastia is more frequent in patients who had the symptoms less than 1 year. There was a statistically significant difference between dendritic and nodular forms of gynecomastia in group 1 patients ($p < 0.01$). One of the possible reasons may be the subjective nature of perceiving the symptoms among the patients. Another possible explanation may be the duration of one year is not enough to document the fibrous state of the disease. On previous reports, mammographic dendritic phase was believed to indicate fibrosis. We think this argument needs further studies evaluating correlation with mammographical and histopathological findings.

Determination of the irreversible fibrous state of gynecomastia may facilitate treatment. Gynecomastia patients with symptoms more than one year presents chronic dendritic phase. The histologic characteristics of fibrous gynecomastia are ductal proliferation with dense, fibrotic stroma (10, 11). Our data showed that diffuse gynecomastia was unexpectedly higher than the dendritic type for the group 2 cases which had the symptoms for 1 to 2 years ($p < 0.001$). We observed that the duration of symptoms of our patients who had dendritic or diffuse gynecomastia visualized by MG was shorter than that recorded in the literature.

It has been reported that dendritic phase, observed in mammography, indicates fibrosis (7, 8, 17, 18). Contrary to literature dendritic gynecomastia is more frequent in patients who had symptom less than one year ($p < 0.01$). A major part of our cases was in progression into dendritic phase within less than one year. Interestingly most of the patients evaluated as in early nodular phase by MG were seen in dendritic phase with US (92%). Our findings may reveal two results. The first one is that the use of imaging methods may be more efficient in stating the reversible phase than deciding upon the duration of symptoms. Secondly, we believe that US could expose the fibrosis earlier than MG.

Although Appelbaum classification is a simple method and it is easy to understand. The role of US in gynecomastia has still been debated. We believe that high-resolution probes can contribute to the evaluation of the developmental stages of gynecomastia through its ability to resolve micro lobulations and spiculations. Ramadan et al. (19) reported that the sonographic characteristics of gynecomastia in men are similar to the early breast development in female adolescents depending on the duration of development. Therefore, Tanner staging may be used in male patients alternatively for the sonographic evaluation of gynecomastia. It is well documented that retroareolar ovoid hyperechoic tissue was identified similar with nodular gynecomastia only in Tanner stage 1. Simple branched duct development is observed in Tanner stage 2, while central hypoechoic star-shaped areas encircled by hyperechoic peripheral rim, reflecting fibro glandular tissue development, are characteristic for Tanner stage 3-4 (20). A retroareolar hypoechoic star shaped area "encircled by hyperechoic peripheral rim" is visualized by high-resolution US in most of our cases. The use of these high-resolution US findings may demonstrate an early phase fibrosis especially in patients visualized by MG as with nodular phase. For this reason, the combination of MG-US, which is not preferred in adolescents, may be effectively used for detecting early stages of fibrosis in adult males.

The relationship between breast cancer and gynecomastia is controversial, with reported coexistence ranging from 2% to 40% (11, 21,

22). The association may be due to elevated levels of estrogens, which may be observed in both conditions. However, no histological transition from gynecomastia to breast cancer has been demonstrated (23). In our study, 28% of our carcinoma patients had coexistent gynecomastia. In one of our carcinoma case, accompanying gynecomastia obscured the visualization of the tumor mass. In the other, the tumor mass was such huge to mimic diffuse gynecomastia (see Figure 4). On the other hand, these two tumors were detected by US. As mentioned in previous papers, US may be useful to differentiate gynecomastia and mass or to detect a mass located within gynecomastia. Our experience reveals that sonography is a complementary tool for the differential diagnoses of mammographically detected abnormalities in men.

Because lobule formation is extremely rare in male breast, some common lesions of the female breast, (e.g. adenosis-fibroadenoma, fibrocystic change and lobular carcinoma) are also rare (1, 21, 24). Thus, it is very important that well-circumscribed masses should be considered as candidates for malignancy. We did not detect well circumscribed lesions corresponding to fibrocystic changes or fibroadenoma in our study. Complex cystic breast masses in men are suggestive of malignancy, and papillary DCIS should be considered in the differential diagnosis (25). Only one carcinoma case (14%) contains anechoic cystic areas in this study.

Common central and subareolar location of breast cancer in men is due to the absence of peripheral terminal ductal lobular units. The locations of the masses were retroareolar in four cases (57%), and eccentric to the nipple in one case (14%) and within the nipple in the other (14%). In the remaining one case, the mass covered the whole breast. These findings are consistent with the previous reports (1, 24). The location of the mass in respect of the nipple could be a determining factor.

Microcalcification appears mainly in carcinoma in situ (DCIS), which is infrequently seen in male cancer (26). Calcifications were found in 7%-31% of male breast cancer patients in different studies (1, 24). Calcifications that are generally considered as benign in women may be an indicator of malignancy in men (21). In accordance with the literature, microcalcification detection rate in our carcinoma cases was found to be 28%.

Eighty-five percent (85%) of male breast cancer has been reported as invasive ductal cancer (23). This study confirms the presence of high percentage value. All our tumors are ductal in origin. In our cases, six of seven cases were invasive carcinoma (86%) five of them were invasive ductal carcinoma. And the remaining case was invasive papillary carcinoma. Pure DCIS without an associated infiltrating ductal cancer is less common (2.3-17%) (23, 25). The single case of DCIS (14%) in our study was of the papillary subtype, which has been described in more than 75% of DCIS cases in men (27). All of our invasive ductal cancers are moderately or poorly differentiated. Giardino et al. (28) reported a markedly higher (90.6%) proportion of estrogen receptor (ER)-positive tumors in men. In our study, all of the four patients (with known hormone receptor status) were ER-positive.

The limitation of our study is the relatively low number of cases and lack of radiopathologic correlation in gynecomastia cases. We could not evaluate the correlation because most of the cases were not operated or did not have biopsy samples.

When we evaluate our cases in the light of literature findings, a hard-fixed and painless mass suggests malignancy, whereas a soft painful mass without skin thickening and nipple retraction may imply gynecomastia. A mass with spiculated or lobulated contour eccentric to the nipple and microcalcifications in the mammogram are findings

that support malignancy. Contrary to these findings subareolar flame-disk shaped nodular radiodensity or non-mass like subareolar density with posterior linear projections radiating into the surrounding fatty tissue indicate gynecomastia. In both of our diagnostic imaging clinics, ultrasonography is considered as the first line imaging method in patients younger than 35 years who have indeterminate or suspicious physical examination findings. Mammography was performed only in cases where suspicious findings were detected by ultrasonographic evaluation. In patients over 35 years of age we think that using both imaging modalities together will be more effective.

In conclusion, Appropriate joint use of diagnostic imaging methods in male breast problems could decrease unnecessary biopsy rates to perform a successful differential diagnosis. Furthermore, mammo-sonographic examination could efficiently differentiate gynecomastia from malignancy as it could determine the reversible phase of gynecomastia as well. Therefore the combination of MG and US in adult gynecomastia cases might determine the time of surgical treatment. Sonographic Tanner staging might be an alternative in order to evaluate gynecomastia evolution in adolescent cases.

Ethics Committee Approval: Ethics committee approval was not requested for this study.

Informed Consent: Written informed consent was obtained from patients who participated in this study.

Peer-review: Externally peer-reviewed.

Author Contributions: Concept - Ö.S.; Design - Ö.S.; Supervision - A.N.K.; Resources - E.Ö.; Materials - E.Ö.; Data Collection and/or Processing - M.T.; Analysis and/or Interpretation - Ö.S.; Literature Search - Ö.S.; Writing Manuscript - Ö.S., A.N.K.; Critical Review - Ö.S.

Conflict of Interest: No conflict of interest was declared by the authors.

Financial Disclosure: The authors declared that this study has received no financial support.

References

1. Gunhan-Bilgen I, Bozkaya H, Ustun E, Memis A. Male breast disease: clinical, mammographic, and ultrasonographic features. *Eur J Radiol* 2002; 43: 246-255. (PMID: 12204407) [\[CrossRef\]](#)
2. Boring CC, Squires TS, Tong T, Montgomery S. Cancer statistics, 1994. *CA Cancer J Clin* 1994; 44: 7-26. (PMID: 8281473) [\[CrossRef\]](#)
3. Volpe CM, Raffetto JD, Collure DW, Hoover EL, Doerr RJ. Unilateral male breast masses: cancer risk and their evaluation and management. *Am Surg* 1999; 65: 250-253. (PMID: 10075303)
4. Adibelli ZH, Oztekin O, Postaci H, Uslu A. The Diagnostic Accuracy of Mammography and Ultrasound in the Evaluation of Male Breast Disease: A New Algorithm. *Breast care* 2009; 4: 255-259. (PMID: 20877664) [\[CrossRef\]](#)
5. Taylor K, Ames V, Wallis M. The diagnostic value of clinical examination and imaging used as part of an age-related protocol when diagnosing male breast disease: an audit of 1141 cases from a single centre. *Breast* 2013; 22: 268-272. (PMID: 23570843) [\[CrossRef\]](#)
6. Munoz Carrasco R, Alvarez Benito M, Munoz Gomariz E, Raya Povedano JL, Martinez Paredes M. Mammography and ultrasound in the evaluation of male breast disease. *Eur Radiol* 2010; 20: 2797-2805. (PMID: 20571799) [\[CrossRef\]](#)
7. Appelbaum AH, Evans GF, Levy KR, Amirkhan RH, Schumpert TD. Mammographic appearances of male breast disease. *Radiographics* 1999; 19: 559-568. (PMID: 10336188) [\[CrossRef\]](#)
8. Gilda C. *Breast imaging companion*. 2 ed. Philadelphia: Lippincott Williams and Wilkins; 2001.
9. *Radiology ACo. Breast Imaging Reporting and Data System*. 4 ed. Reston, VA: American College of Radiology 2003.
10. Michels LG, Gold RH, Arndt RD. Radiography of gynecomastia and other disorders of the male breast. *Radiology* 1977; 122: 117-122. (PMID: 318597) [\[CrossRef\]](#)
11. Chantra PK, So GJ, Wollman JS, Bassett LW. Mammography of the male breast. *AJR Am J Roentgenol* 1995; 164: 853-858. (PMID: 7726037) [\[CrossRef\]](#)
12. Chen L, Chantra PK, Larsen LH, Barton P, Rohitopakarn M, Zhu EQ, Bassett LW. Imaging characteristics of malignant lesions of the male breast. *Radiographics* 2006; 26: 993-1006. (PMID: 16844928) [\[CrossRef\]](#)
13. Sneige N, Holder PD, Katz RL, Fanning CV, Dekmezian RH, Shabb NS, Singletary SE. Fine-needle aspiration cytology of the male breast in a cancer center. *Diagn Cytopathol* 1993; 9: 691-697. (PMID: 8143548) [\[CrossRef\]](#)
14. Munn S. When should men undergo mammography? *AJR Am J Roentgenol* 2002; 178: 1419-2140. (PMID: 12034609) [\[CrossRef\]](#)
15. Crichlow RW, Galt SW. Male breast cancer. *Surg Clin North Am* 1990; 70: 1165-1177. [\[CrossRef\]](#)
16. Cooper RA, Gunter BA, Ramamurthy L. Mammography in men. *Radiology* 1994; 191: 651-656. (PMID: 8037795) [\[CrossRef\]](#)
17. Chantra PK S, So GJ, Wollman JS, Bassett LW. *Diagnosis of diseases of the breast*. 2 ed. Philadelphia, Pa: Saunders; 2005.
18. Osborne M. Breast development and anatomy. In: Harris J, Lippman M, Morrow M, et al (eds) *Diseases of the breast*, 2nd edn. Lippincott-Raven, Philadelphia, pp 1-14.
19. Ramadan SU, Gokharman D, Kacar M, Kosar P, Kosar U. Assessment of vascularity with color Doppler ultrasound in gynecomastia. *Diagn Interv Radiol* 2010; 16: 38-44. (PMID: 20151357)
20. García CJ, Espinoza A, Dinamarca V, Navarro O, Daneman A, García H, Cattani A. Breast US in children and adolescents. *Radiographics* 2000; 20: 1605-1612. (PMID: 11112814) [\[CrossRef\]](#)
21. Dershaw DD, Borgen PI, Deutch BM, Liberman L. Mammographic findings in men with breast cancer. *AJR Am J Roentgenol* 1993; 160: 267-270. (PMID: 8424331) [\[CrossRef\]](#)
22. Chen PH, Slanetz PJ. Incremental clinical value of ultrasound in men with mammographically confirmed gynecomastia. *Eur J Radiol* 2014; 83: 123-129. (PMID: 24161780) [\[CrossRef\]](#)
23. Heller KS, Rosen PP, Schottenfeld D, Ashikari R, Kinne DW. Male breast cancer: a clinicopathologic study of 97 cases. *Ann Surg* 1978; 188: 60-65. (PMID: 208472) [\[CrossRef\]](#)
24. Mathew J, Perkins GH, Stephens T, Middleton LP, Yang WT. Primary breast cancer in men: clinical, imaging, and pathologic findings in 57 patients. *AJR Am J Roentgenol* 2008; 191: 1631-1639. (PMID: 19020230) [\[CrossRef\]](#)
25. Yang WT, Whitman GJ, Yuen EH, Tse GM, Stelling CB. Sonographic features of primary breast cancer in men. *AJR Am J Roentgenol* 2001; 176: 413-416. (PMID: 11159083) [\[CrossRef\]](#)
26. Hittmair AP, Liningner RA, Tavassoli FA. Ductal carcinoma in situ (DCIS) in the male breast: a morphologic study of 84 cases of pure DCIS and 30 cases of DCIS associated with invasive carcinoma--a preliminary report. *Cancer* 1998; 83: 2139-2149. (PMID: 9827718) [\[CrossRef\]](#)
27. Visfeldt J, Scheike O. Male breast cancer. I. Histologic typing and grading of 187 Danish cases. *Cancer* 1973; 32: 985-990. (PMID: 4751929) [\[CrossRef\]](#)
28. Giordano SH, Cohen DS, Buzdar AU, Perkins G, Hortobagyi GN. Breast carcinoma in men: a population-based study. *Cancer* 2004; 101: 51-57. (PMID: 15221988) [\[CrossRef\]](#)