



Follicular Thyroid Carcinoma with Metastases to the Breast: An Unusual Case

Memeye Metastaz Yapan Folliküler Tiroid Kanseri: Nadir Bir Olgu

Çağatay Arslan¹, Hasan Şenol Coşkun², Sema Sezgin Göksu², Özden Çandır³

¹Department of Medical Oncology, MedicalPark Hospital, İzmir University, İzmir, Turkey

²Department of Medical Oncology, Faculty of Medicine, Akdeniz University, Antalya, Turkey

³Department of Pathology, Faculty of Medicine, Süleyman Demirel University, Isparta, Turkey

ABSTRACT

A 57-year-old woman was admitted with a left breast mass. Metastatic follicular thyroid carcinoma (FTC) was diagnosed two years previously with excision of a parietal bone lesion. Two sessions of radioactive I-131 were administered after total thyroidectomy due to multiple metastases in the lungs and bones. A regimen of single agent adriamycin was given when the disease progressed. Partial remission was obtained after 6 cycles of chemotherapy. After five months following chemotherapy she was admitted with a left breast mass. Surgical excision revealed FTC metastasis. The patient has a stable disease twelve months after metastasectomy. Metastasis of thyroid cancer to the breast is a very rare occurrence. Only a few cases were reported. It is important to distinguish metastatic malignancies from primary breast tumors to avoid destructive surgery and maintain the appropriate treatment of the primary tumor.

Key words: Breast cancer, metastasis, Follicular thyroid cancer

ÖZET

Elli yedi yaşında bir kadın sol memede kitle nedeniyle başvurdu. İki yıl önce pariyetal kemik lezyonu eksizyonu ile folliküler tiroid kanseri (FTK) metastazı tanısı almıştı. Total tiroidektomi sonrasında; akciğerlerde ve kemiklerde multipl metastazlarının olması nedeniyle 2 kez radyoaktif iyot 131 uygulanmıştı. Daha sonra hastalık progresyonu nedeniyle tek ajan adriamisin kemoterapisi başlandı ve 6 kür sonrasında kısmi yanıt elde edildi. Kemoterapi sonlandırıldıktan 5 ay sonra sol memede kitle nedeniyle başvurdu. Memedeki kitle eksize edildi ve patoloji FTK metastazı olarak raporlandı. Metastazektomi sonrasında 12. ayda stabil hastalık ile izlenmektedir. Tiroid kanserinin meme metastazı nadir bir durumdur ve çok az sayıda olgu rapor edilmiştir. Morbiditesi yüksek cerrahi girişimlerden kaçınmak ve primer tümöre yönelik uygun cerrahi girişimi uygulayabilmek açısından metastatik kanserin primer meme tümörlerinden ayrımı önemlidir.

Anahtar sözcükler: Meme kanseri, metastaz, Folliküler tiroid kanseri

Introduction

Distant metastases of differentiated thyroid cancer are usually to the lung and bone. Less common sites of metastases are the brain, liver, kidneys, and skin (1, 2). Thyroid cancer metastasis to the breast was reported only in four cases and one of them was follicular sub-type (3-6).

Solid tumor metastasis to the breast is rare. 0.43% of breast malignancies were reported as secondary tumors (7). The most common tumors metastasizing to the breast are malignant melanoma, lymphoma and lung cancer (8). Treatment procedures change regarding histopathological diagnosis. In this paper we describe a patient with follicular thyroid cancer developing breast metastasis during the follow up diagnosis and treated with surgical excision.

Case Report

A 57-year-old woman was admitted with a left breast mass. Her family history was unremarkable. Twenty six months earlier a parietal bone lesion was excised surgically. Pathology showed follicular thyroid carcinoma (FTC) metastasis. Thyroid ultrasonography showed a solid nodule of 2 cm in diameter in the left lobe. Multiple nodular lesions were seen in both lungs on computerized tomography (CT) scan. Pathological activity was determined in the 4th cervical spine and 10th right rib on bone scintigraphy. Palliative external radiotherapy was administered to the vertebrae. Total thyroidectomy was performed followed by 300 mCi radioactive Iodine 131 (I-131) treatment. Control I-131 scan showed no pathologic activity. Thyroid suppression treatment and zoledronic acid were begun. After twelve months from the diagnosis, serum thyroglobulin levels increased and pathological activity was seen in the 10th right rib and cervical vertebrae at control I-131 scan. A second dose of 350 mCi radioactive I-131 was given. When progression was seen in the cervical vertebrae single agent adriamycin at a dose of 50 mg/m² every 3 weeks was begun. After six cycles of chemotherapy partial response was obtained. Chemotherapy lasted after six cycles and zoledronic acid, and levothyroxin treatments were continued.

Address for Correspondence/Yazışma Adresi:

Çağatay Arslan, Department of Medical Oncology, MedicalPark Hospital, İzmir University, İzmir, Turkey
Phone / Tel.: +90 232 399 50 50 e-mail / e-posta: arslancagatay@yahoo.com

Received / Geliş Tarihi: 28.07.2012
Accepted / Kabul Tarihi: 23.11.2012

After 5 months following chemotherapy when she was on zoledronic acid and thyroid suppression treatment, a left breast mass of 2x2 cm in size in the left upper quadrant occurred. Mammography showed a 2.5 cm mass lesion without calcification. Ultrasonography revealed a lobulated solid lesion. Routine biochemistry and blood counts were normal. Serum-free tri-iodothyronine, thyroxine, and thyroid stimulating hormone levels were; 4.620 pg/mL (2.3-4.2), 0.307 pg/mL (0.89-1.8) and 0.046 mU/mL (0.35-5.5), respectively. A fine needle aspiration of the left breast lesion showed malignant cells but the differential diagnosis was inadequate. A core biopsy revealed metastasis of follicular thyroid carcinoma with trabecular variant. Control I-131 scan showed pathological activity in the left breast and cervical vertebrae. Lesion in the left breast were excised surgically. Pathological diagnosis was the same as the core biopsy (Figure 1-3). She had increasing cervical pain spreading to the arms in the last months. Bisphosphonate treatment was continued for bone metastasis. After twelve months following surgery to the breast she had no recurrent lesions either in the breast or other solid organs, and was on supportive care.

Discussion and Conclusions

The incidence of thyroid cancer is about 3.7 to 4 per 100,000 population. It is the most common tumor of the endocrine system and accounts for 1% of the malignancies (9). Follicular thyroid carcinoma constitutes about 10-15% of thyroid cancers (9). Almost 10% of patients with papillary carcinoma of thyroid and up to 25% of those with follicular carcinoma have distant metastasis, and half of them have metastases at the time of diagnosis (2). Follicular thyroid carcinoma is known to have frequent metastasis by the hematogenous route most commonly to the lung, bone and lymph nodes (2). This case was firstly diagnosed during excision of a parietal bone lesion. Skull metastasis of tumors are relatively rare compared to other skeletal sites. They originate mostly from the lung, breast or prostatic carcinoma; most frequent bone metastasizing tumours. Even distant metastases might be observed at the time of diagnosis or at subsequent follow-up; thyroid carcinoma presenting with skull metastasis is a rare occurrence (10, 11). Rare sites for distant metastasis of thyroid carcinoma are the kidney, brain, skin, and adrenal glands (2, 12). Thyroid cancer metastasis to the breast was reported only in four cases and one of them was a follicular sub-type (3-6). Breast mass was enucleated surgically in this case after the diagnosis of thyroid cancer metastasis with a core biopsy. Complete surgical excision of distant metastasis in differentiated thyroid carcinoma might offer a prolonged survival. Surgical excision of the breast lesion might help to differentiate the primary tumor and metastasis, and is also part of the treatment approach.

Secondary neoplasms of the breast are uncommon. The incidence of breast metastases from extra-mammary tumors were reported as between 2 to 4% of all breast malignancies. However in an autopsy series the incidence was reported between 1.4 and 6.6% (7, 12). Malignant melanoma, lymphoma, lung cancer, ovarian carcinoma, soft tissue sarcoma are the most common cancers to metastasize to breast (8, 13, 14). Metastases from osteosarcoma, gastric cancer, cervical, vaginal and endometrial carcinomas to the breast were also reported sporadically in the literature (8, 13-15). To our knowledge this is the fifth case of thyroid cancer and second case of follicular sub-type reported metastasizing to the breast (3-6).

The suspicion of breast metastasis is generally simple when a known primary tumor is present. However, one third of the cases originating from outside the breast were represented to spread from an occult

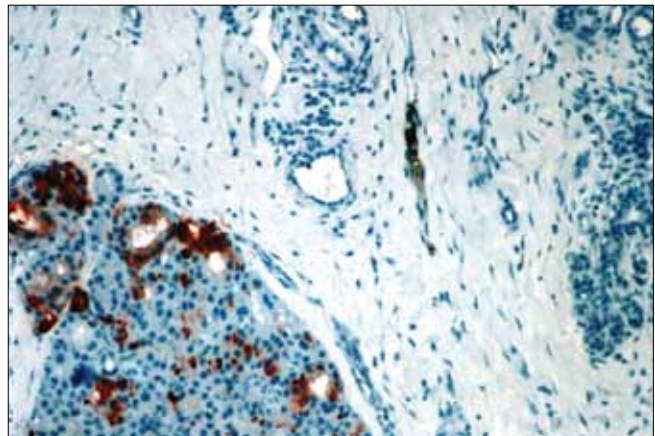


Figure 1. Breast metastasis of follicular thyroid carcinoma: immunostaining with anti-Tg. Positive staining of thyroid follicular carcinoma cells and negative staining of breast tissue cells. (X100)

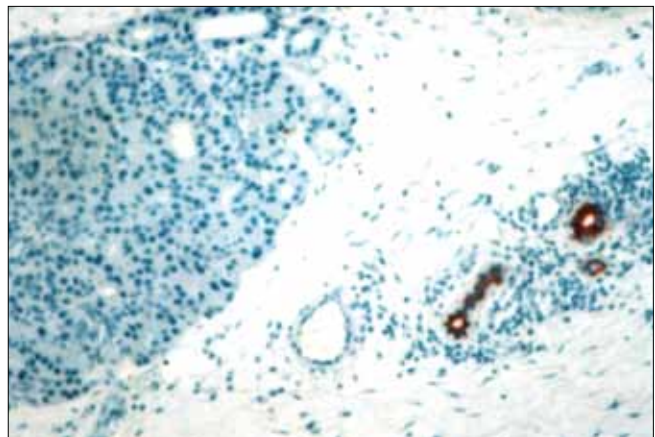


Figure 2. On immune-histochemical staining with pan-CK, epithelial cells of breast tubuli reveal positive staining and tumor cells have no staining. (X100)

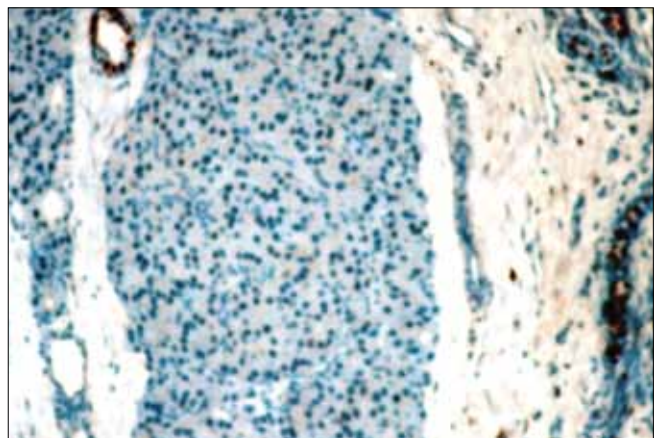


Figure 3. Estrogen receptor immuno-staining is positive at breast tubuli epithelial cells and negative at tumor cells. (X100)

primary (7). Also, breast carcinoma might occur as a second primary during the course of another cancer being diagnosed. Secondary non-mammalian neoplasms involving the breast were reviewed from a 90 year archive of the 20th century by Georgiannos et al. (7) and it was reported that hematologic tumors predominated, particularly in more

recent years, and carcinomas were less frequent overall; but numerous in the earlier part of the century.

It is important to differentiate metastatic malignancies from primary breast tumors to avoid destructive surgery such as mastectomy or maintaining the appropriate treatment of the primary tumor. However cytological or radiological investigations might sometimes be inconclusive. Surgical excision is generally diagnostic and provides the treatment of the metastatic tumor. Histological similarities which might be present between breast carcinoma and metastatic tumors and also within these metastatic malignancies might cause diagnostic difficulties for the pathologist. Immuno-histochemical staining is helpful for the accurate diagnosis at this point. Anti-thyroglobulin antibody, as in this case, is a good marker in confirmation of the pathological diagnosis of differentiated thyroid cancer metastasis.

In conclusion; this was an interesting case who presented initially with skull metastasis and was diagnosed as follicular thyroid carcinoma from the excision of the parietal bone lesion and metastasizing to the breast in the follow up as a very rare occurrence mimicking a second primary tumor of the breast itself. Immuno-histopathological evaluation was helpful in the differential diagnosis. Moreover breast metastasis of thyroid cancer was adequately treated with surgical excision. Clinicians must be aware of atypical metastases of FTC cases.

Conflict of Interest: No conflict of interest was declared by the authors.

Peer-review: Externally peer-reviewed.

Informed Consent: Written informed consent was obtained from patients who participated in this case.

Author Contributions: Concept - Ç.A., H.Ş.C.; Design - Ç.A.; Supervision - H.Ş.C.; Materials - Ç.A., S.S.G.; Data Collection and/or Processing - Ç.A., Ö.Ç.; Analysis and/or Interpretation - Ç.A., H.Ş.C.; Literature Review - Ç.A.; Writer - Ç.A.; Critical Review - Ç.A., H.Ş.C.

Financial Disclosure: The authors declared that this study has received no financial support.

Çıkar Çatışması: Yazarlar çıkar çatışması bildirmemişlerdir.

Hakem değerlendirmesi: Dış bağımsız.

Hasta Onamı: Yazılı hasta onamı bu olguya katılan hastalardan alınmıştır.

Yazar Katkıları: Fikir - Ç.A., H.Ş.C.; Tasarım - Ç.A.; Denetleme - H.Ş.C.; Malzemeler - Ç.A., Ö.Ç.; Veri toplanması ve/veya işlemesi - Ç.A., S.S.G.; Analiz ve/veya yorum - Ç.A., H.Ş.C.; Literatür taraması - Ç.A.; Yazıyı yazan - Ç.A.; Eleştirel İnceleme - Ç.A., H.Ş.C.

Finansal Destek: Yazarlar bu çalışma için finansal destek almadıklarını beyan etmişlerdir.

References

1. Toubert ME, Hindie E, Rampin LE, Al-Nahhas A, Rubello D. Distant metastases of differentiated thyroid cancer: diagnosis, treatment and outcome. *Nucl Med Rev Cent East Eur* 2007; 10:106-109. (PMID: 18228215)
2. Shaha AR, Ferlito A, Rinaldo A. Distant metastasis from thyroid and parathyroid cancer. *ORL J Otorhinolaryngol Relat Spec.* 2001; 63:243-249. (PMID: 11408821) [CrossRef]
3. Angeles-Angeles A, Chable-Montero F, Martinez-Benitez B, Albores-Saavedra J. Unusual metastases of papillary thyroid carcinoma: report of 2 cases. *Ann Diagn Pathol* 2009; 13:189-196. (PMID: 19433299) [CrossRef]
4. Tan PK, Chua PK, Pob WT. Thyroid papillary carcinoma with unusual breast metastasis. *Ann Acad Med Singapore* 1991; 20:801-802. (PMID: 1803974)
5. Loureiro MM, Leite VH, Boavida JM, Raposo JF, Henriques MM, Limbert ES, Sobrinho LG. An unusual case of papillary carcinoma of the thyroid with cutaneous and breast metastases only. *Eur J Endocrinol* 1997; 137:267-269. (PMID: 9330591) [CrossRef]
6. Chisholm RC, Chung EB, Tuckson W, Khan T, White JE. Follicular carcinoma of the thyroid with metastasis to the breast. *J Natl Med Assoc* 1980; 72:1101-1104. (PMID: 7441790)
7. Georgiannos SN, Chin J, Goode AW, Sheaff M. Secondary neoplasms of the breast: a survey of the 20th Century. *Cancer* 2001; 92:2259-2266. (PMID: 11745279) [CrossRef]
8. Akcay MN. Metastatic disease in the breast. *Breast* 2002; 11:526-528. (PMID: 14965721) [CrossRef]
9. Tai P, Moud RF, Pryszyzhnyuk AY, Gristchenko VG, Obodovsky IA. Descriptive epidemiology of thyroid carcinoma. *Current Oncology* 2003; 10:54-65.
10. Shamim MS, Khurshheed F, Bari ME, Chisti KN, Enam SA. Follicular thyroid carcinoma presenting as solitary skull metastasis: report of two cases. *J Pak Med Assoc* 2008; 58:575-577. (PMID: 18998315)
11. Inci S, Akbay A, Bertan V, Gedikoğlu G, Onol B. Solitary skull metastasis from occult thyroid carcinoma. *J Neurosurg Sci* 1994; 38:63-66. (PMID: 7965145)
12. McIntosh IH, Hooper AA, Milis RR, Greening WP. Metastatic carcinoma within the breast. *Clin Oncol* 1976; 2:393-401. (PMID: 1024766)
13. Toombs BD, Kalisher L. Metastatic disease to the breast: clinical, pathologic, and radiographic features. *AJR Am J Roentgenol* 1977; 129:673-676. (PMID: 409241) [CrossRef]
14. Hajdu SI, Urban JA. Cancers metastatic to the breast. *Cancer* 1972; 29: 1691-1696. (PMID: 4337956) [CrossRef]
15. Nielsen M, Andersen JA, Henriksen FW, Kristensen PB, Lorentzen M, Ravn V, Schiødt T, Thorborg JV, Ornvold K. Metastases to the breast from extramammary carcinomas. *Acta Pathol Microbiol Scand Sect A* 1981; 89:251-256. (PMID: 7315321)